

Massive gastrointestinal bleeding associated with contralateral mucosal abrasion by percutaneous endoscopic gastrostomy tube*

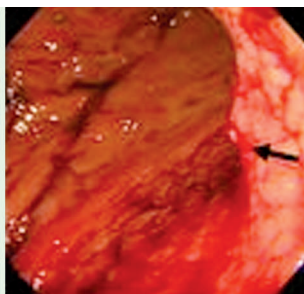
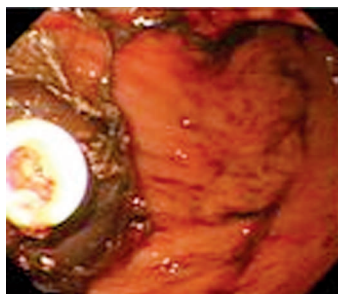


Fig. 1 The balloon-type percutaneous endoscopic gastrostomy (PEG) tube was located at the anterior wall of the gastric body (a). A bleeding vessel was visible on the posterior wall of the gastric body, opposite the tube (b).

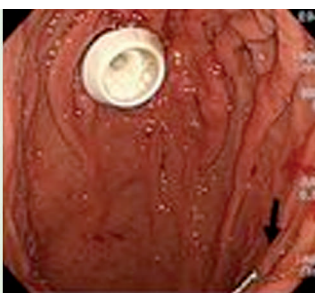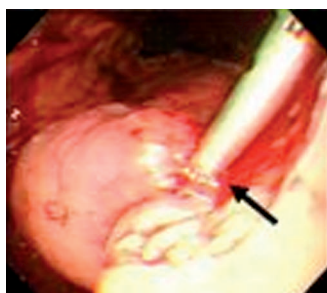


Fig. 2 One hemoclip was placed to achieve hemostasis (a). Three days later, successful hemostasis was confirmed (b).

Note the substitute pull-type PEG tube on the anterior wall of the gastric body, and the attached clip (arrow) on the opposite site.

Massive upper gastrointestinal bleeding (UGIB) related to percutaneous endoscopic gastrostomy (PEG) has been described in sporadic reports [1–4]. After reviewing 246 PEG procedures performed between 2002 and 2008, we identified four episodes (1.6%) of massive UGIB. Three episodes (in two patients) might result from an unreported mechanism and are presented here.

The first patient was a 61-year-old man with hypoxic encephalopathy, who passed tarry stool 2 months after undergoing PEG replacement with a balloon-type tube (24 Fr; Wilson-Cook, Winston-Salem, North Carolina, USA). Endoscopy revealed a bleeding ulcer at the posterior wall of the gastric body, opposite the tube. Endoscopic hemostasis was carried out with epinephrine injection and hemoclipping. Ten months later, hemorrhage recurred at the same location (Fig. 1). After successful hemostasis with hemoclipping (Resolution clip; Boston Scientific, Natick, Massachusetts, USA) (Fig. 2a), a pull-type PEG (24 Fr; Wilson-Cook) was substituted.

Follow-up endoscopy 3 days later confirmed successful hemostasis (Fig. 2b). The other patient was an 88-year-old man with stroke, who passed maroon-colored stool 1 week after undergoing PEG replacement with the same type of tube. Endoscopy revealed a 1.5-cm oozing ulcer at the opposite site to the PEG, similar to the patient described above. The bleeding ulcer was managed with endoscopic epinephrine injection and high-dose omeprazole infusion (8 mg/h). Unfortunately, although hemostasis was successful, this patient died of subsequent aspiration pneumonia.

Previous reports of PEG-related UGIB have focused on mucosal ulceration resulting from excessive tension between the external and internal bumpers as the cause of hemorrhage [1,3]. Massive UGIB owing to contralateral mucosal abrasion by the tube has not been reported. In our two patients, the location of the bleeders opposite the internal bumper might be related to mucosal abrasion by the tube [5]. The balloon-type tube (Wilson-Cook) had a segment distal to the balloon, which might abrade the posterior gastric wall and cause ulceration. To conclude, contralateral abrasion by the PEG tube may rarely lead to massive UGIB.

* Yao-Chun Hsu and Jai-Jen Tsai contributed equally to this paper.

Acknowledgment

We are indebted to Miss Betty, Tzu-en Lin and Mr. Alex, Jen-hao Lin for assistance in this study. This report was supported by Tomorrow Medical Foundation.

Endoscopy_UCTN_Code_CPL_1AH_2AI

Y.-C. Hsu¹, J.-J. Tsai², C.-L. Perng^{3,4}, H.-J. Lin^{1,4}

¹ Division of Gastroenterology, Department of Medicine, Lotung Poh-Ai Hospital, I-Lan, Taiwan

² Division of Gastroenterology, Department of Medicine, Veterans General Hospital-Taipei, Taiwan

³ Division of Gastroenterology, Department of Medicine, National Yang-Ming University Hospital, I-Lan, Taiwan

⁴ School of Medicine, National Yang-Ming University, Taipei, Taiwan

References

- Mackenzie SH, Fang JC, Kuwada SK. Severe upper-GI bleeding in a patient with PEG tube placement by the radiologic push method. *Gastrointest Endosc* 2007; 65: 935–936
- Anagnostopoulos GK, Kostopoulos P, Arvanitidis DM. Buried bumper syndrome with a fatal outcome, presenting early as gastrointestinal bleeding after percutaneous endoscopic gastrostomy placement. *J Postgrad Med* 2003; 49: 325–327
- Chong C, Derigo L, Brown D. Massive gastric bleeding: a rarely seen subacute complication of percutaneous endoscopic gastrostomy. *Intern Med J* 2007; 37: 787–788
- Cappell MS, Lufadeju A, Challa A et al. Seeding of the percutaneous endoscopic gastrostomy tract from esophageal squamous cell cancer presenting as an actively bleeding malignant gastric ulcer: a novel clinicoendoscopic presentation. *South Med J* 2008; 101: 35–39
- Kanie J, Akatsu H, Suzuki Y et al. Mechanism of the development of gastric ulcer after percutaneous endoscopic gastrostomy. *Endoscopy* 2002; 34: 480–482

Bibliography

DOI 10.1055/s-0029-1214705

Endoscopy 2009; 41: E144

© Georg Thieme Verlag KG Stuttgart · New York · ISSN 0013-726X

Corresponding author

Hwai-Jeng Lin, MD, FACC

Division of Gastroenterology

Department of Medicine

Lotung Poh-Ai Hospital

83 Nan Chang St.

Lotung

I-Lan County 265

Taiwan

hjlin@mail.pohai.org.tw